


small incision calcaneus fractures



Michael Swords, DO
Michigan Orthopedic Center
Chief, Orthopedic Surgery
Director of Orthopedic Trauma
Sparrow Hospital
Lansing MI

objectives

- how to reduce a fracture
- Overview of my sinus tarsi technique
- Outcomes- does it work?

my current technique....

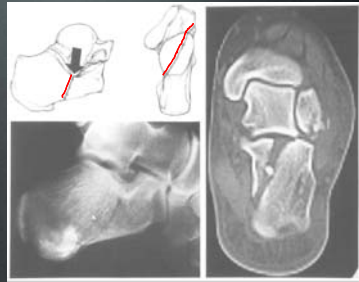
- small incision or sinus tarsi approach
- all cases since 2008
- over 150 cases
- all types including open fractures

Understand....

- this is not a compromise on reduction
 - reduction is the same
- articular reduction is directly visualized with headlight
- still trying to re establish bony morphology to ENTIRE CALCANEUS

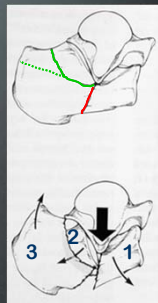
Pathoanatomy

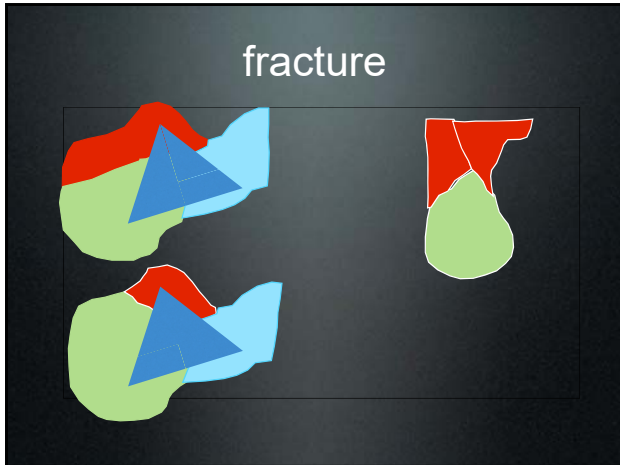
- Primary fracture line
- "Constant" fragment

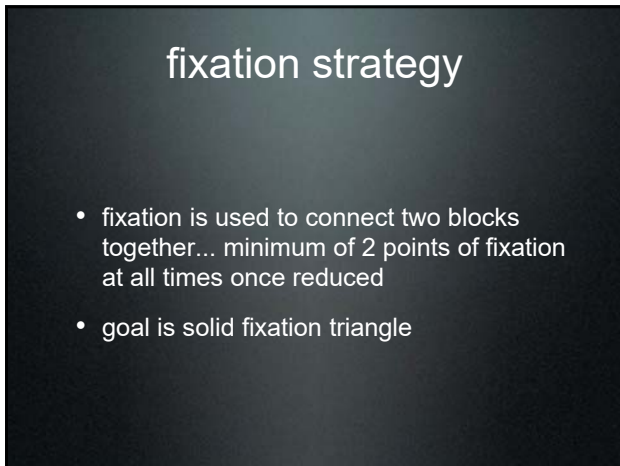

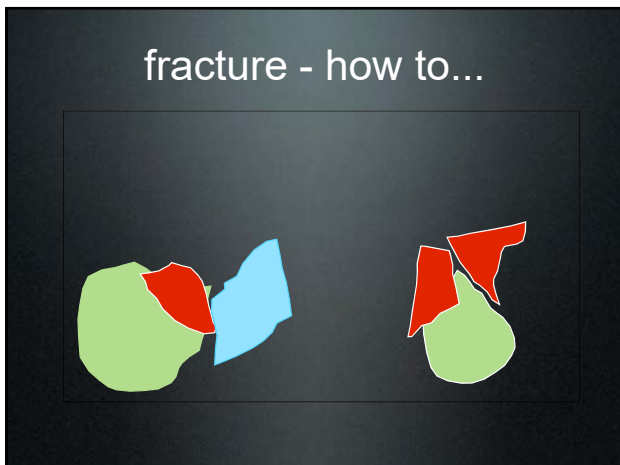Pathoanatomy

- Secondary fracture line
- Extends posteriorly through tuberosity
- Creates 3 parts











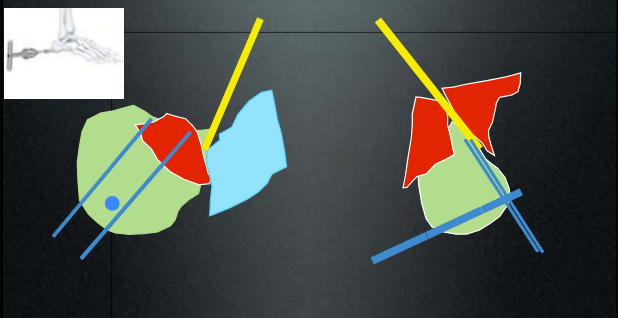
insert schantz pin



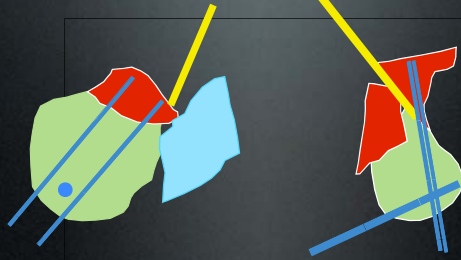
insert 2 kwires in tuber just inside medial wall



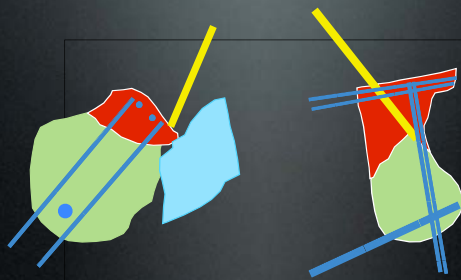
insert elevator to reduce medial wall/restore height



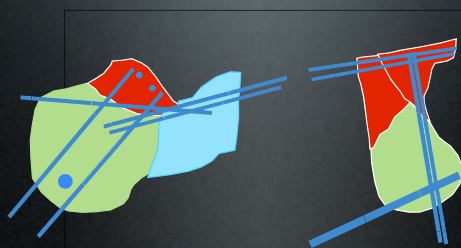after reduced advance k
wires to hold reduction of
tuberosity



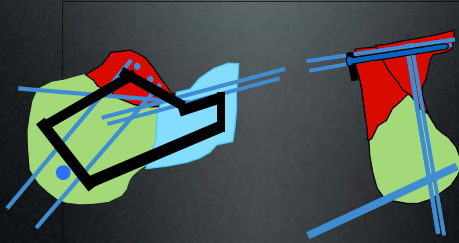
final reduction of articular
surface- provisional k wires



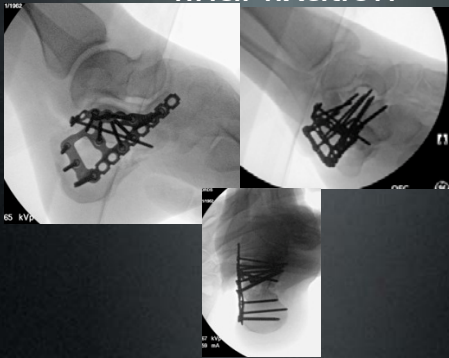reduce anterior process
and critical angle-
more k wires!!



insert plate to maintain articular reduction, lag thru plate- leave k wires in until fixation complete



final fixation



insert plate to maintain articular reduction, lag thru plate- leave k wires in..

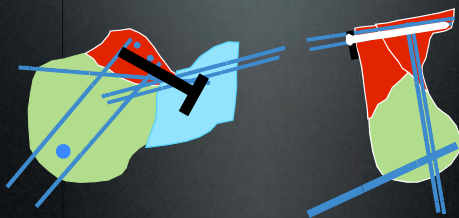
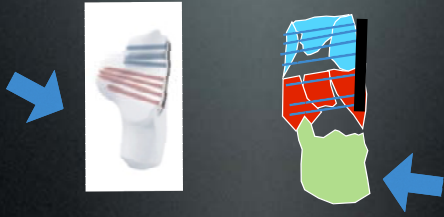


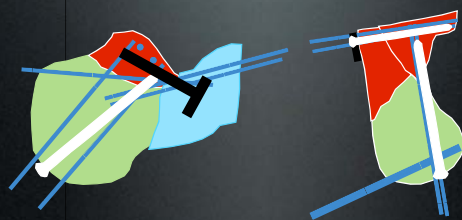plate does not provide fixation in tuberosity



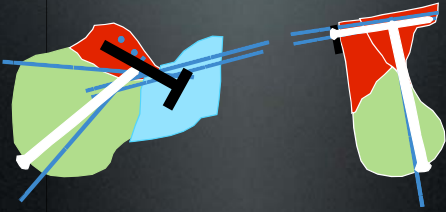
need supplemental screws




insert screws for tuberosity
medial wall-
2 points of fixation



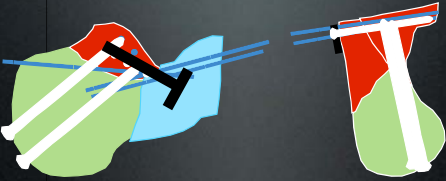
remove k wire to make room for 2nd screw..
2 points fixation



insert second screw



may remove last tuberosity
k wire



raft joint

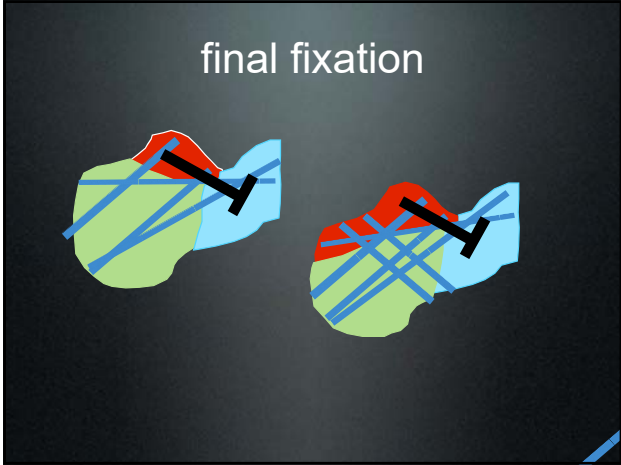


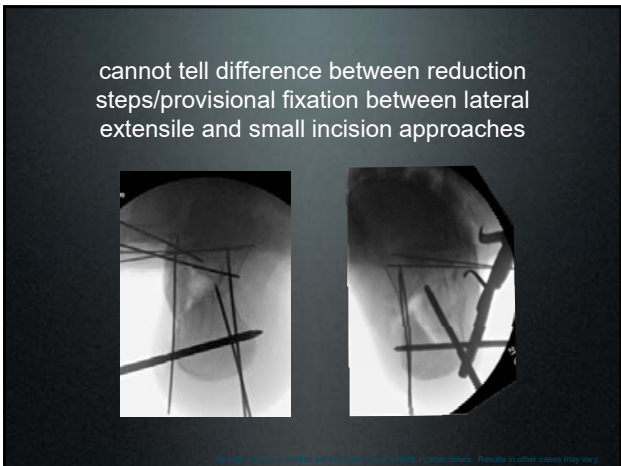
insert screw from central
tuberosity to anterior
process- remove wires

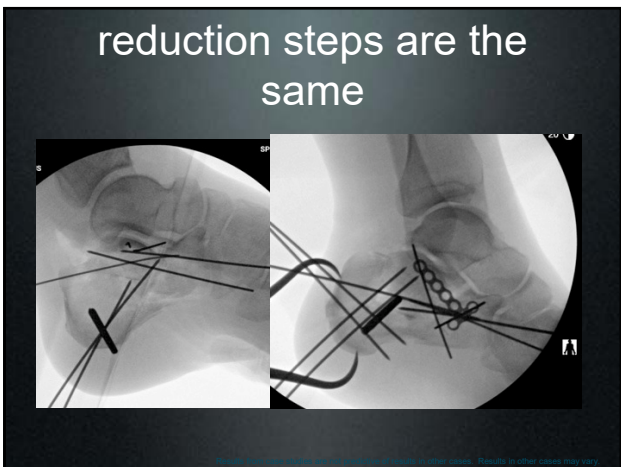


screw pattern for tongue
fractures

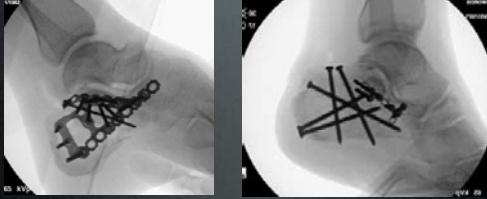








quality of reduction is identical

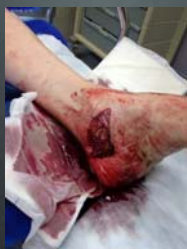

Results from this research are not intended to be used in other cases. Results in other cases may vary.

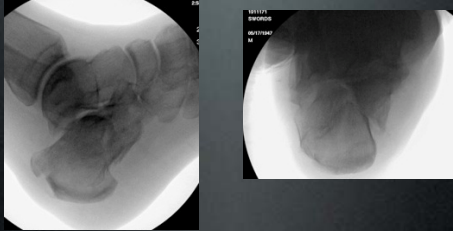
case example

- 72 year old farmer
- fell off loft
- open wound medially

ED

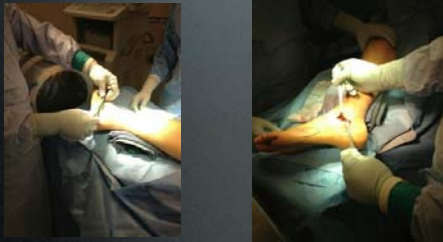

injury films



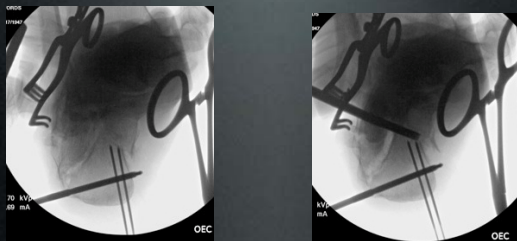
Results from this procedure are not intended to be used in other cases. Results in other cases may vary.

incision starts 1cm below fibula and 1cm anterior and runs 2-3cm



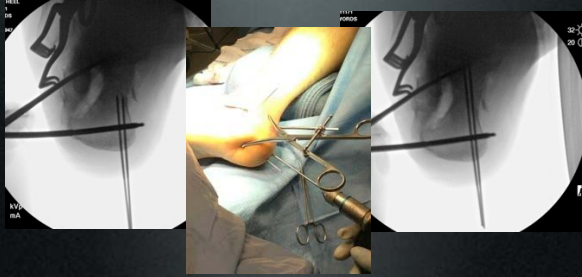
Results from this procedure are not intended to be used in other cases. Results in other cases may vary.

k wires along medial wall from tuberosity then use elevator to lift while manipulating tuber with Schantz pin



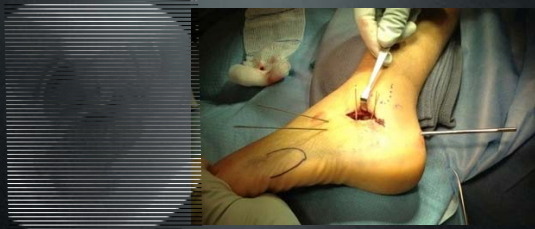Results from this procedure are not intended to be used in other cases. Results in other cases may vary.

after medial wall reduction
advance k wires



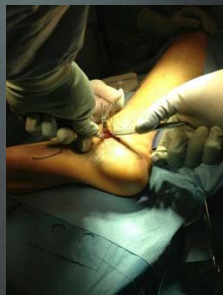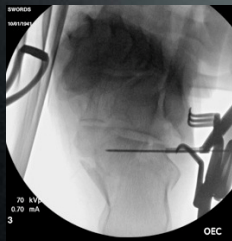
Results from this procedure are not predictable in other cases. Results in other cases may vary.

initial k wires placed for
articular reduction



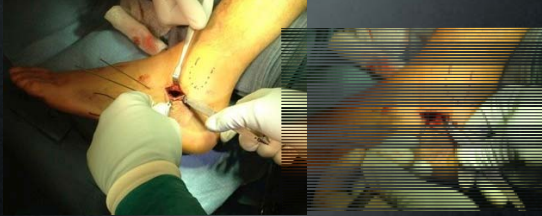Results from this procedure are not predictable in other cases. Results in other cases may vary.

reduce posterior facet-
looking directly into joint



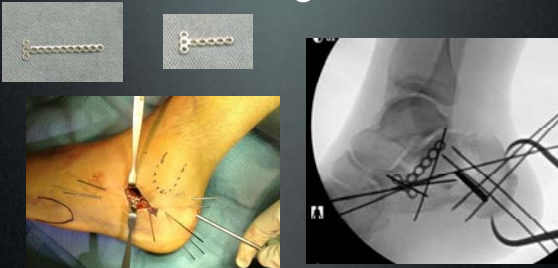
Results from this procedure are not predictable in other cases. Results in other cases may vary.

reduce anterior process
and advance k wires



Results may vary depending on the location of the fracture in other cases. Results in other cases may vary.

previously used 2.4 plate
with 2.7 lag screws



Results may vary depending on the location of the fracture in other cases. Results in other cases may vary.

provisional fixation
complete

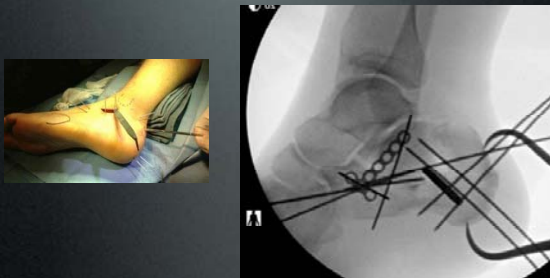
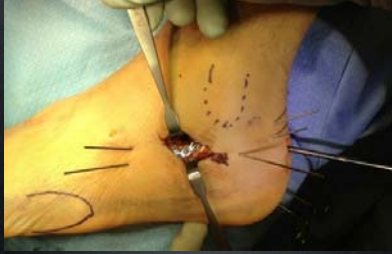
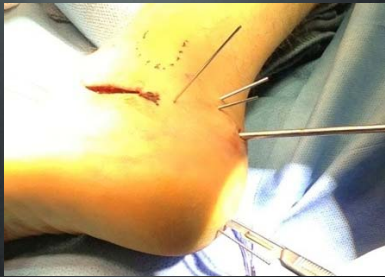
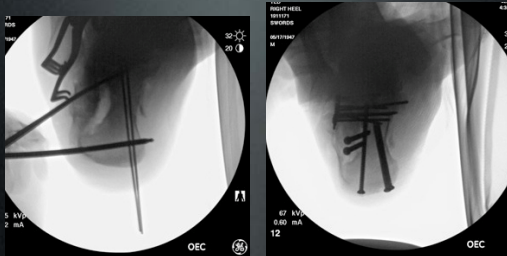
plate in - fixation of articular surface complete

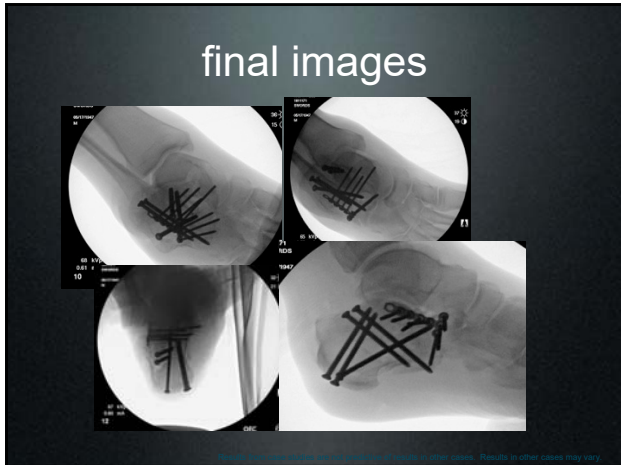


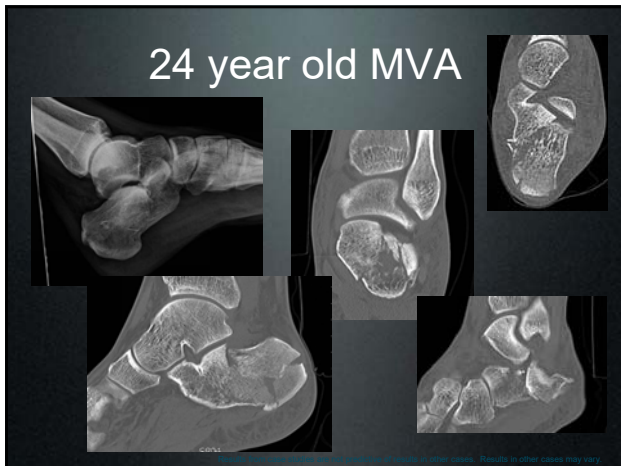
supplemental 4.0 screws inserted from tuberosity

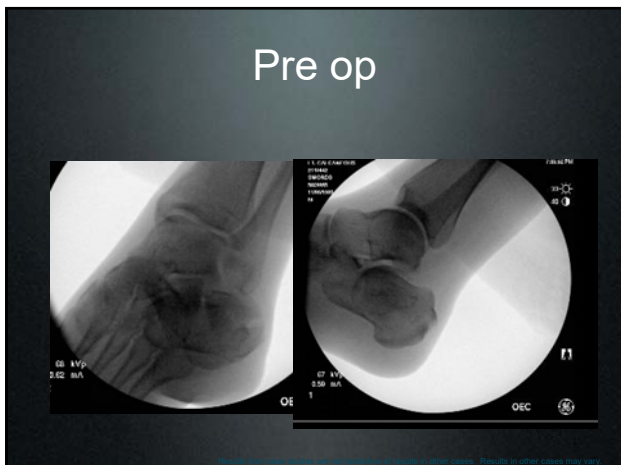


4.0 screws inserted to stabilize medial wall/tuberosity reduction

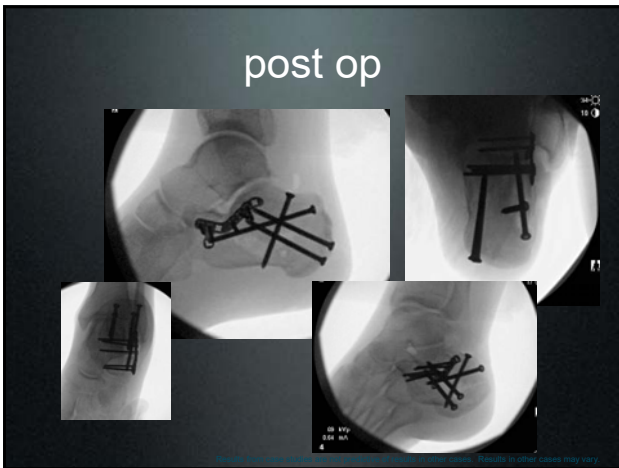


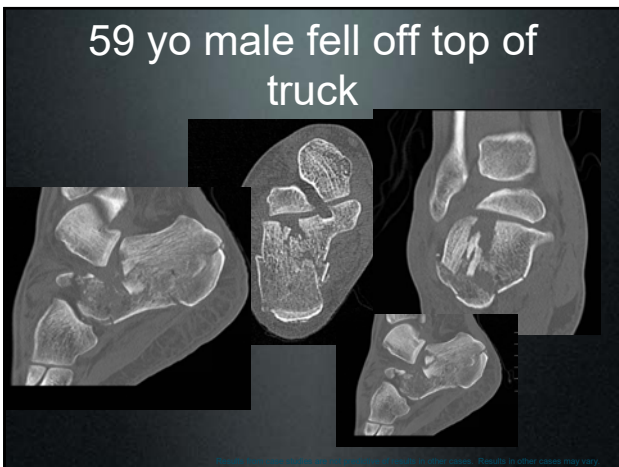



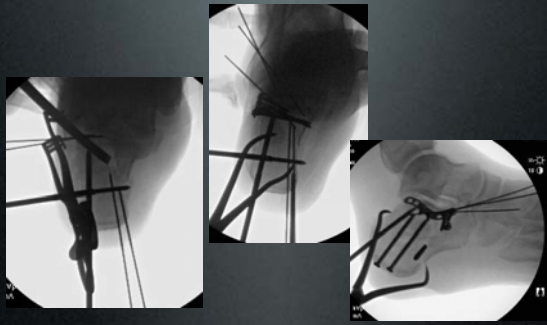





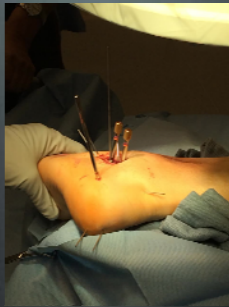


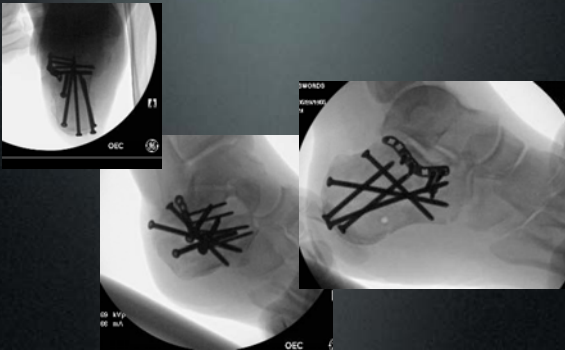
reduction



Results may vary. Results are not guaranteed. Results in other cases. Results in other cases may vary.

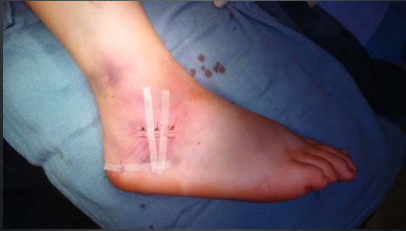

final



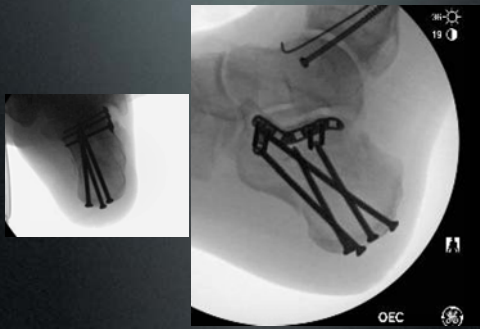
Results may vary. Results are not guaranteed. Results in other cases. Results in other cases may vary.

tissue friendly- final closure



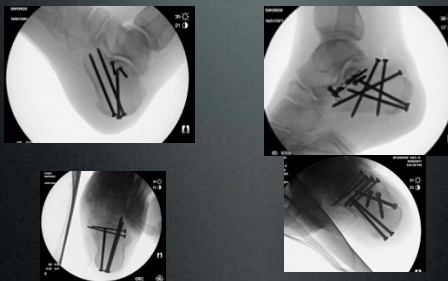
Results from this research are for informational purposes only. Results in other cases may vary.

bilateral



Results from this research are for informational purposes only. Results in other cases may vary.

easier fracture patterns require less fixation
more difficult patterns require more fixation



Results from this research are for informational purposes only. Results in other cases may vary.

Outcomes

- No difference in functional outcome between Extensile lateral and small incision approaches
- Lower reoperation rate – 19.2 vs. 50%
- Shorter time to FWB- 12 vs. 15 wks
- Longer fu in extensile group
- Further eval in progress...

summary

- hard fractures
- small incisional is possible for most fractures- WITH EXPERIENCE
- should not be a compromise on reduction

Thank You